

Unusual Terminal Branch Of The Ulnar Nerve Superficial To The Carpal Tunnel

Ioannis A. Ignatiadis, George N. Nomikos, Vassiliki E.Tsiamba, Spyridon F. Xeinis, Adrian M. Avram, Christos Yiannakopoulos, Nicolas E. Gerostathopoulos.

Hand surgery-Upper limb and Microsurgery Dept, KAT Hospital of Attika, Athens, Greece

Abstract

A 34-year-old woman, who presented with bilateral carpal tunnel symptoms, underwent sequential bilateral open carpal tunnel decompression. At the time of surgery an abnormal nerve was found running superficial to the transverse carpal ligament, between the thenar and hypothenar eminences, on both sides. This corresponds to the terminal common digital sensory branch from the ulnar nerve to the fourth web side. This nerve is at a high risk of injury during carpal tunnel decompression, since it appears unexpectedly, and very superficial, at the place of incision.

Key words:

Rezumat

Cuvinte cheie:

INTRODUCTION

Several patterns of anomalous branches of the ulnar nerve have been described in the literature. In 1874, Turner described the variation that we report, as a sensory branch of the ulnar nerve that arises in the forearm and travels in an anomalous course to become the common digital nerve to the fourth web space. At the wrist it passes superficial to the transverse carpal ligament in the area of the incision for a carpal tunnel decompression.

CASE REPORT

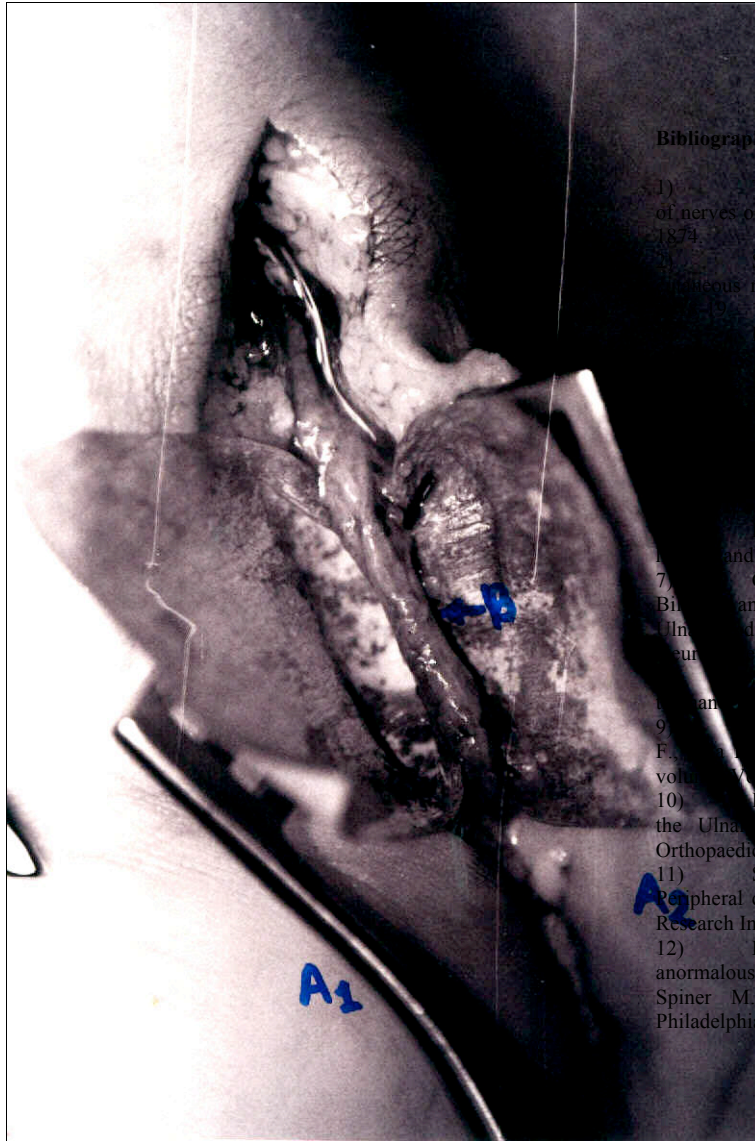
A 34-year-old, right-handed Caucasian woman presented with a typical bilateral carpal tunnel syndrome. The diagnosis was confirmed by nerve conduction tests. In January 1998, a left carpal tunnel decompression was carried out in standard fashion and a nerve was found directly under the skin. Since the nerve looked too thin to be the median or the ulnar nerve, the incision was extended proximally for about 6 cm, this showed the nerve to be a branch of the ulnar nerve (fig

1,2) and it was accompanied by a small artery. The branch was retracted ulnar-wards and a release of the transverse carpal ligament confirmed the median nerve to be in its usual position. Ten months later, a right carpal tunnel decompression was carried out and an identical ulnar branch was found on the right side. The results of both operations were satisfactory.

DISCUSSION

The absence of reports of this anomaly since it was first described in 1874 suggest that this is a rare occurrence, but it is of surgical importance since it is located at the point of incision for carpal tunnel decompression.

When performing a carpal tunnel decompression, it is important to be aware of possible anatomical variations that although rare, can cause complications. Had the procedures described in this case-report been carried out endoscopically, the likely outcome would have been division of the anomalous branch



Bibliography:

- 1) Turner W. : Further examples of variations in arrangement of nerves of the human body. *Journal Anatomy – Physiology* 8: 297, 1874.
- 2) Stopford J. S. B. : The variations in distribution of the peripheral nerves of the hand digits. *Journal Anatomy* 53 : 14-25 , 1889.
- 3) Kaplan E. B. , Variations of the Ulnar nerve at the wrist. *Journal of Hand and Wrist Joint diseases* : 24 : 85-88, 1963.
- 4) Winkelman N. Z., Spinner M.: A variant high sensory branch of the Median nerve to the third web space. *Bull. Hosp. Joint Diseases* 33 : 161, 1973.
- 5) Mc Frlane R.M, Mayer J.R., Hugill S.V. Further studies on the Anatomy of the Ulnar nerve at the wrist. *The hand* 1976.
- 6) Denman E.E. An unusual branch of the Ulnar nerve in the hand. *Journal of Hand Surgery* 1977: 9, 92-3.
- 7) Galzio R, J., Magliani V., Lucantoni D., D' Arrigo C. Bilateral anomalous course of the Ulnar nerve at the wrist causing Ulnar and Median nerve compression syndrome. *Journal of Neurological Surgery*. 67: 754-56, 1987.
- 8) Spinner M. Kaplan's functional and surgical Anatomy of the hand. Third edition Philadelphia : Lippincott, 1984 : 206-35.
- 9) Anatomical Study of the Ulnar Nerve in the Hand. *Bonnel F., Journal of Hand Surgery, British and European volume* 10-B No. 2 June 1985.
- 10) Dalvin L B., Bergfield T.G., Aulicino P.L., Variations of the Ulnar Nerve. *Orthopaedic Review. A surgical perspective. Orthopaedic Review*. 22(1): 33-9, Jan. 1993.
- 11) Stappaerts K.H., Van Hess j., Van de Broek E. A Peripheral cutaneous nerve distribution to the fingers. *Physiotherapy Research International*. 1(1) : 41-49, 1996.
- 12) Kaplan E.B., Spinner M. Normal and anomalous innervation patterns in the upper extremity. In: Omer G.E., Spiner M. (Eds) *Management of peripheral nerve problems* Philadelphia, W. B. Saunders, 1980: 75-115